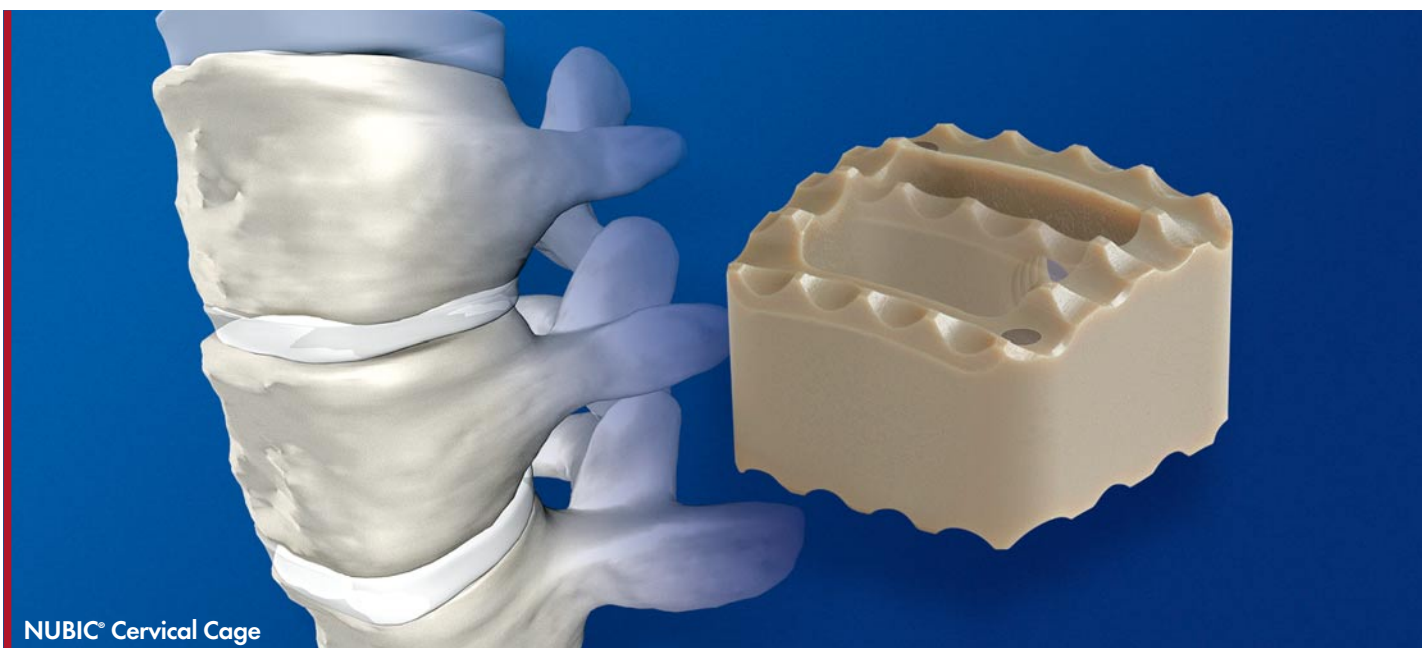


NUBIC®

Vertebral Body Fusion - simple and efficient



NUBIC®

Vertebral Body Fusion - simple and efficient

The simple and efficient selection in cervical interbody fusion. Using an anterior approach and following cervical discectomy the NUBIC® cervical implant is indicated for use in:

- Intervertebral disc prolapse
- Disc luxation or herniation
- Mechanical instability
- Calcification of the posterior structures
- Osteochondrosis
- Spinal canal stenosis

PEEK Optima™ LT, a revolutionary biocompatible thermoplastic solution for in-vivo applications, is particularly suitable as an implant material. Since its introduction more than 20 years ago, the polymer has become ever more the material of choice for applications requiring outstanding resistance to chemicals, heat, steam, radiation and wear. While being all but totally inert, this polymer combines superior strength, stiffness and impact resistance while allowing excellent post operative imaging of the operative site. For more information have a look at our technical brochure.

SPECIFIC ADVANTAGES:

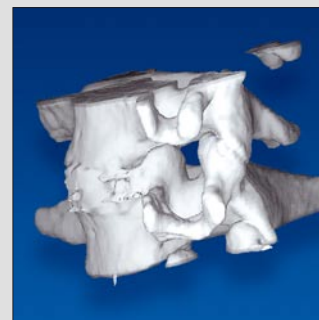- **Artifact-Free in MRI technology**
 - ➔ Optimal postoperative control
- **Titanium markers**
 - ➔ Easy identification and positioning
- **Excellent biocompatibility**
 - ➔ In-vivo, PEEK™ is all but totally inert
- **Toothed, superior and inferior surfaces**
 - ➔ Assuring a secure seating of the implant
- **Wide opening for solid fusion**
 - ➔ Allowing good bony in-growth
- **Oblong form**
 - ➔ In accordance with the established Smith-Robinson technique
- **Curved surface**
 - ➔ Ideal adaption to the vertebral body

HEIGHT	LENGTH	WIDTH	ARTICLE NUMBER	
			WITH STRUT	WITHOUT STRUT
4	13	14	N041314	NB041314
5	13	14	N051314	NB051314
6	13	14	N061314	NB061314
7	13	14	N071314	NB071314
8	13	14	N081314	NB081314

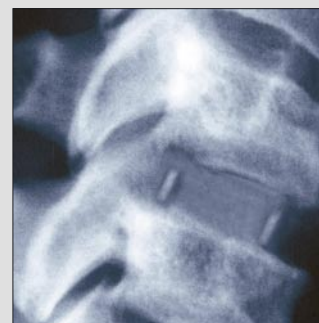
Implants available single packed and sterile, ready to use.



NUBIC®: Vertebral body fusion - simple and efficient



The three dimensional depiction shows the excellent biomechanical integration of the implant



Bony integration is clearly seen at six months post operative

